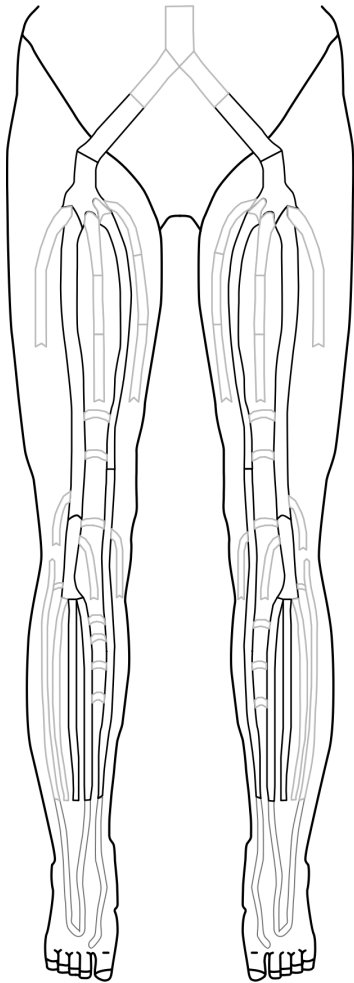


DOB: 1985-07-01 **Age:** 32
Gender: M

Study Time: 01:55 PM
Reading Group: Unassigned HEARTPLACE
Referring Group: Unassigned HEARTPLACE
Sonographer: Emilie^Demo

Study Quality: Excellent



- Normal
- Mildly reduced
- Moderately reduced
- Severely reduced
- Absent
- Inconclusive

RIGHT	
	Reflux Time, s
EIV	2.1
CFV	1.98
FV	2.3
GSV AK	2.7
GSV BK	2.01
POP	2.04
PTV	2.09
PER	2.2

Right Findings:

There is no evidence of deep venous thrombosis of the right lower extremity.

Left Findings:

There is no evidence of deep venous thrombosis of the left lower extremity.

Conclusions:

No evidence of deep vein thrombosis of the lower extremities with normal venous return.

June 15, 2018 08:59 AM EDT
Demo Doctor
Electronically Signed on CoreWeb

